



PATIENT

Trampas Crase

PRESENTING CLINICAL SIGNS

History: Heart murmur. Asymptomatic. Sedated with IV butorphanol and midazolam for echo but still whining and panting.

SPECIES

Canine

ECHOCARDIOGRAM FINDINGS

2D, m-mode, color flow and doppler imaging is available. Normal MV leaflets with no obvious prolapse. Trace mitral regurgitation. Normal left atrial dimension. Normal LV diameter with adequate myocardial function. Normal LV wall dimensions. The tricuspid valve appears subjectively normal, trace tricuspid regurgitation. The right heart is normal. No overt evidence of pulmonary arterial hypertension. The pulmonic and aortic valves are normal in morphology and mobility. The aortic valve is normal with a mildly elevated outflow velocity. A trivial perimembranous is suspected just below the aortic valve with left to right flow. No AI. Pulmonic outflow velocities are normal. No pulmonic insufficiency. No pericardial or pleural effusion noted. No cardiac tumors observed.

BREED

Mix

SEX

Male

AGE

24 weeks

CARDIAC CHART

WEIGHT

38lbs

INTERPRETED BY

Maggie Machen Lamy,
DVM, DACVIM
(Cardiology)

CANINE CARDIAC PARAMETERS	MR VMAX (m/s)	TR VMAX (m/s)	LA/AO (Boon method)	LA/AO (Heart Base; Swe)	FS (%)	EF (%)	EPSS (cm)
NORMAL PARAMETER	4.5-5.5	<2.7	1.3	<1.6	28-40	40-100	<0.6
PATIENT	NM	NM	NM	1.2NM	47	79	0.25
CANINE CARDIAC PARAMETERS	HR (BPM)	AV VMAX (m/s)	PV MAX (m/s)	BODY WEIGHT (kg)	LA 2D short axis Base view (cm)	LVIDd Avg; 2D and m-mode short axis (cm)	LVIDs Avg; 2D and m-mode short axis (cm)
NORMAL PARAMETER	50-100	0.7-1.7	0.7-1.6	BELOW	BELOW	BELOW	BELOW
PATIENT	NM	2.2	1.2	17.2	2.4	3.0	1.6
*Normal chamber parameters expressed as a mean value (SD)				3	1.27 (5.3)	2.46 (2.46)	1.36 (5.5)
BODY WEIGHT DEPENDENT PARAMETERS				5	1.40 (4.5)	2.74 (5.2)	1.60 (4.7)
*Note: All measurements based upon multi-modal images and methods. An average value is reported.				10	1.50 (3.8)	3.27 (3.5)	2.06 (3.1)
				15	1.83 (2.0)	3.71 (2.4)	2.43 (2.1)
				20	2.02 (1.9)	4.14 (2.2)	2.80 (2.0)
				25	2.18 (2.4)	4.48 (2.9)	3.10 (2.5)
				30	2.33 (3.3)	4.83 (3.9)	3.39 (3.4)
				35	2.48 (4.3)	5.17 (5.0)	3.69 (4.5)
				40	2.62 (5.2)	5.48 (6.1)	3.96 (5.4)
				50	2.88 (7.1)	6.07 (8.3)	4.46 (7.4)

INTERPRETATION OF THE FINDINGS & FURTHER RECOMMENDATIONS

The only cause of a murmur identified is mildly increased flow velocity through the aortic root. No obvious aortic valve abnormalities visualized and there is no subaortic ridge seen. In the absence of structural abnormalities this is considered a benign flow murmur. This type of outflow abnormality is heart rate dependent and will vary with hydration/volume changes as well. Additionally, a trivial perimembranous VSD is suspected, which appears hemodynamically insignificant. Often shunts of this size will close as the puppy ages and follow up is recommended. Trace MR and TR are likely of little consequence. No additional defects are observed.

INVOICE

32063

DATE

8/1/23

HOSPITAL NAME

New Frontier Animal
Medical Center

REFERRING VET

Dr. Gunther



PATIENT

Trampas Crase

No cardiac medications are indicated at this time. Monitor for any development of cough, labored breathing or exercise intolerance.

SPECIES

Canine

No cardiac contraindication for general anesthesia is seen.

BREED

Mix

Assuming the murmur persists, recommend recheck echocardiogram in 1 year to ensure no progressive issues are seen, sooner if any clinical signs arise in the interim.

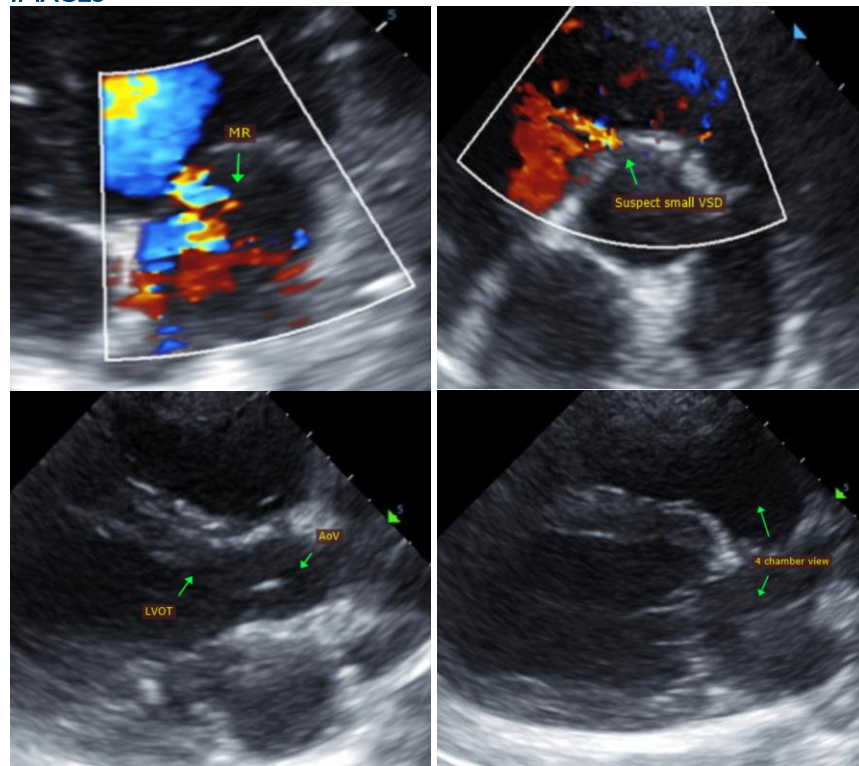
SEX

Male

IMAGES

AGE

24 weeks



WEIGHT

38lbs

INTERPRETED BY

Maggie Machen Lamy,
DVM, DACVIM
(Cardiology)

IMAGING PERFORMED BY

G. Gunther, DVM

HOSPITAL NAME

New Frontier Animal
Medical Center

The information and recommendations provided are based on the images presented by the referring veterinarian. No evaluation can be communicated regarding pathology that was not visible in the image/video clips provided.

REFERRING VET

Dr. Gunther

Thank you for this referral. This report was generated using transcription software, and minor dictation errors may be present. If the clinical or image interpretation does not parallel your findings or if I can be of any further assistance, please contact me.

INVOICE

32063

Maggie Machen Lamy, DVM
Diplomate of the American College of Veterinary Internal Medicine (Cardiology)
info@sonopath.com

DATE

8/1/23



PATIENT

Trampas Crase

SPECIES

Canine

BREED

Mix

SEX

Male

AGE

24 weeks

WEIGHT

38lbs

INTERPRETED BY

Maggie Machen Lamy,
DVM, DACVIM
(Cardiology)

**IMAGING
PERFORMED BY**

G. Gunther, DVM

HOSPITAL NAME

New Frontier Animal
Medical Center

REFERRING VET

Dr. Gunther

INVOICE

32063

DATE

8/1/23